



UDC 591.4:615.371:636.52/58

DOI: 10.48077/scihor.25(12).2022.32-40

## Histoarchitectonics of the Harderian gland of chickens in the post-vaccination period

Tetiana Budnik\*, Svitlana Hural'ska, Oleh Pinsky, Hennady Hryshchuk, Volodymyr Honcharenko

Polissia National University  
10008, Staryi Blvd., 7, Zhytomyr, Ukraine

### Article's History:

Received: 09/27/2022

Revised: 11/09/2022

Accepted: 11/30/2022

### Suggested Citation:

Budnik, T., Hural'ska, S., Pinsky, O., Hryshchuk, H., & Honcharenko, V., (2022). Histoarchitectonics of the Harderian gland of chickens in the post-vaccination period. *Scientific Horizons*, 25(12), 32-40.

**Abstract.** Understanding the effect of vaccination on the body of chickens is impossible without exploring the morphology of the immune defence organs. The purpose of the study was to identify morphological changes in the Harderian gland of the Haysex Brown chickens aged 1, 15, 25, 50, 75, 100 and 120 days under the influence of vaccination. The following methods were used in the study: anatomical, histological, light-optical, morphometric, and statistical. Histological preparations of the Harderian gland of chickens of different ages (1, 15, 25, 50, 75, 100 and 120 days) of the vaccinated and unvaccinated groups were analysed. The features of the organ structure, its lymphoid structures and their types of forms were explored on histological preparations of the chicken Harderian gland. According to histological studies, it was established that this is a complex tubular lobular gland, which consists of secretory lobules with ducts. The interlobular connective tissue contains a significant number of lymphocytes, plasma cells, and other cells. In vaccinated chickens at 25 days of age, the presence of diffuse lymphoid tissue was noted, which was not observed in the control group, and at 50 days of age - the development of a nodular form of lymphoid tissue, the maximum number of which was observed at 100 days of age. In chickens of 75, 100, and 120 days of the age of the experimental group, the amount of lymphoid tissue in the Harderian gland increased, which was noted in the interlobular connective tissue and secretory lobules. It has been proven that the chicken gland, as a peripheral organ of immune defence, is developed at 50 days of age in both the control and vaccinated groups. The study of morphological changes in the Harderian gland of the poultry of different ages is an important tool for the development of preventive vaccination protocols in modern poultry farming. The results of the study should be considered when improving the technology of rearing and exploitation of chickens to ensure high vitality and, accordingly, productivity

**Keywords:** poultry, histological changes, lymphoid structures, secretory lobules, vaccination



Copyright © The Author(s). This is an open access article distributed under the terms of the Creative Commons Attribution License 4.0 (<https://creativecommons.org/licenses/by/4.0/>)

\*Corresponding author

## INTRODUCTION

The ability to understand the function, pathology, and repair of organ systems is limited without knowledge of their normal structure. The immune defence organs of chickens consist of central and peripheral departments that work in concert to establish protective reactions against external pathogenic factors. The Harderian gland - a peripheral organ of the immune defence of chickens, which is involved in the activation and final differentiation of B-lymphocytes, and plasma cell proliferation. One of the main problems in poultry farming is infectious diseases. Vaccination is an important method of protecting poultry on farms.

Decreased vaccination efficiency and the development of immunodeficiency states are caused by the adverse effects of man-made factors. In many cases, immune disorders are caused by a defective immune system (Song *et al.*, 2021). In birds, a well-functioning immune system is of vital importance, namely, protection against pathogens, and the development of an immune response to vaccination (Nair, 2022). J. Madej *et al.* (2018) indicate that outbreaks of infectious diseases in poultry are associated with an overload of immune defences by virulent vaccine strains. Admittedly, any factor that reduces the immune response affects production parameters. Many factors, including infectious and non-infectious, cause immunosuppression in chickens (Gimeno & Schat, 2018).

Poultry is constantly exposed to various immune stresses, one of which is vaccination. The latter is used both to prevent infection and to reduce morbidity and mortality (Feng *et al.*, 2012). Multiple vaccinations are associated with high stress, which suppresses immune function (Kaab *et al.*, 2018). In poultry farms, inactivated vaccines are frequently used in high doses and repeatedly, with short intervals, which can cause stress to the immune system (Yang *et al.*, 2011; Feng *et al.*, 2012). Stress alters immune responses (Wilkinson *et al.*, 2011; Schat & Skinner, 2022). Immunosuppression in chickens is a very important factor but, therewith, is underestimated in the development of pathology (Schat & Skinner, 2022).

Combination vaccines are mostly preferred for the prevention of chicken diseases, as using a single dose of the drug against two or more infections reduces labour costs and mortality of the bird itself caused by vaccination (Yang *et al.*, 2016; Wit *et al.*, 2017). Mixed infections pose significant obstacles to the organisation of specific infectious disease prevention schemes, which is why a large number of immunisations are used, and the timing of their implementation frequently overlaps. However, immunisation is still the most crucial measure for controlling infections, although the frequent use of live vaccines has contributed to the evolution of new strains (Dey *et al.*, 2019).

According to the study by P. Saelao *et al.* (2018), the resistance of birds to specific diseases, in particular

Newcastle disease, is associated with the immune response of the Harderian gland. According to Frahm and Mohammadpour (2015) and Klecowska-Nawrot *et al.* (2015), the Harderian gland performs various functions: moisturising, cleansing, protecting, and being a source of pheromones. In this case, the immune response is particularly crucial (Jahan *et al.*, 2018). The Harderian gland, along with other peripheral immune defences, is involved in general and local immunity (Jahan *et al.*, 2018).

Microscopic examination of the Harderian gland demonstrated that it is a multilobular gland, with each lobe constructed of secretory acini (Beheiry *et al.*, 2020). The superficial cells of the glandular body produce serous secretion, and the deep cells produce mucous secretion (Mobini, 2012). In their studies, J. Klecowska-Nawrot *et al.* (2016) observed the presence of lymphoid cells in the glandular septa of birds and the secretory lobules, in particular, in their centre. A significant number of plasma cells were located in the glandular part of the organ. Plasma cells are in close contact with epithelial cells and closely envelop the glandular ducts (Nagy *et al.*, 2022). B. Mobini (2012) observed the presence of plasma cells in the interlobular connective tissue trabeculae, under the capsule, and near the main duct. A small number of plasma cells are located in the interlobular connective tissue partitions of the gland. In their studies, R. Beheiry *et al.* (2020) observed that glandular ducts are established from a single layer of prismatic epithelial cells surrounded by myoepithelial cells. Lymphoid cells, namely lymphocytes, macrophages, and granulocytes, are located in the subepithelial layer and the lumen of the glandular lobules (Rana *et al.*, 2020). A fairly large number of lymphocytes and plasma cells are located in the central and apical parts of the secretory lobules, the intercalated part of the gland (Klecowska-Nawrot *et al.*, 2016). Thus, the study of the morphological state of the immune system organs, including the Harderian gland, is of great importance.

The purpose of the study is to establish the cytological and histological features of the development of the Harderian gland of chickens at different stages of multivaccine prevention of infectious diseases. Objectives of the study: to determine the cytological and histological features of the Harderian gland of chickens of 1, 15, 25, 50, 75, 100, and 120 days of age; to determine the histoarchitectonics of the glandular gland of chickens at different vaccination periods.

## MATERIALS AND METHODS

For the experiment, a group of one-day-old Haysex Brown chickens was selected, and reared in the conditions of the "Solotvyn Poultry Farm" branch of the "Green Val" Limited Liability Company in the Staryi Solotvyn village, Berdychiv district, Zhytomyr region, which were divided into two groups of 70 chickens each: control (no vaccinations were

performed) and experimental (chickens were vaccinated according to the vaccination plan for repair stock). The study was conducted in 2020-2022.

The study was conducted in the educational and research clinical diagnostic laboratory of the Polissia National University. The material was the Harderian gland of chickens aged 1, 15, 25, 50, 75, 100, and 120 days selected from the control and experimental groups. The anatomical study included the slaughter and exsanguination of chickens, dissection and removal of organs. Chickens of 1, 15, 25, 50, 75, 100, and 120 days of age were slaughtered using the method of acute exsanguination under ether anaesthesia.

After slaughter, the Harderian gland of chickens was weighed on a Kern ACJ/ACS laboratory balance with an accuracy of 0.001 g. Histological studies were performed according to the generally accepted methods of tissue fixation and histological sections. For histological examination, the Harderian gland of chickens was selected, which was fixed in a 10-12% aqueous solution of neutral formalin for 48 hours, then washed with tap water for 24 hours, dehydrated with ethyl alcohol of increasing concentration (40%, 50%, 70%, 96%, 100%), followed by embedding in paraffin. Histological sections, up to 5-10  $\mu\text{m}$  thick, were made on a sledge microtome. To explore the morphology of cells and tissues, sections of the Harderian gland were stained with hematoxylin and eosin by the Van Gieson method.

To obtain objective data on the structural organisation of the chicken gland, morphometric methods of study were used. The study was performed using a Primo Star light microscope (Carl Zeiss, Germany) and Image Scope software.

Histological specimens were examined and photographed using a digital camera mounted in a Primo Star microscope (Carl Zeiss, Germany) and connected to a personal computer. Statistical processing of the study results was performed on a personal computer using variational and statistical methods using Statistica 6.0 (StatSoft

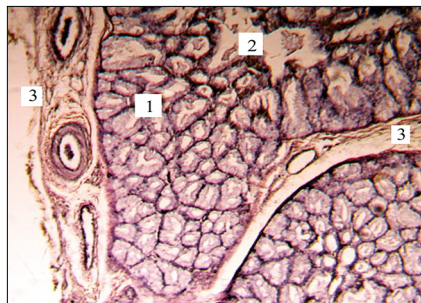
Inc., USA). The reliability of the data obtained was assessed by the Fisher's F test. The difference between the two values was considered significant at  $P < 0.05$ ,  $P < 0.01$ .

When working with animals, the provisions of Article 26 of the Law of Ukraine No. 3447-VI of 10/16/2012 "On the Protection of Animals from Cruelty" (Law of Ukraine No. 3447-VI), "General Ethical Principles for Animal Experiments" approved at the First National Congress on Bioethics (Reznikov, 2003), the requirements of the European Convention for the Protection of Vertebrate Animals Used for Research and Other Scientific Purposes (European Convention, 1986), and the Universal Declaration for the Humane Treatment of Animals (Universal Declaration, 2007).

## RESULTS AND DISCUSSION

The Harderian gland of the experimental and control chickens is located medial to the eyeball, between the orbit and periorbit. Organometric studies have established that the absolute weight of the Harderian gland of one-day-old chickens of the experimental and control groups practically did not vary, but in chickens of 15 days of age (after three times vaccination) this indicator significantly increased in the experimental group compared to the control and amounted to  $0.049 \pm 0.003$  g ( $P < 0.01$ ), while in the control group –  $0.041 \pm 0.002$  g. In addition, a significant increase in the absolute weight of the organ was observed in chickens 50 days of age. Therewith, in this age period, the maximum values of the absolute weight of the organ were noted, which amounted to  $0.095 \pm 0.003$  g ( $P < 0.01$ ) in the experiment and  $0.088 \pm 0.001$  g in the control.

The histological examination established that the gland is covered with a connective tissue capsule, from which the septa extend into the parenchyma of the organ. Van Gieson staining identified collagen fibres in the interlobular connective tissue (Fig. 1). The glandular capsule contains adipose tissue, and elastic, collagen, and reticular fibres.



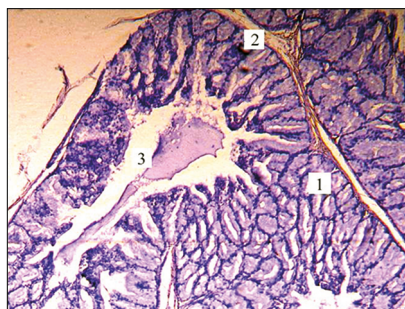
**Figure 1.** The microscopic structure of the Harderian gland of a 15-day-old chicken of the control group:  
1 – secretory lobe; 2 – lumen of the secretory lobe; 3 – interlobular connective tissue

**Note:** Van Gieson method. x 200

**Source:** photo by the authors

Partitions divide the gland parenchyma into secretory lobules. It was established that each lobule of

the organ has a cavity containing a secretion produced by the glandular cells (Fig. 2).



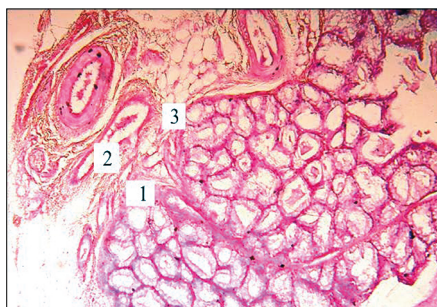
**Figure 2.** The microscopic structure of the Harderian gland of a 25-day-old chicken of the experimental group:  
1 – secretory lobe; 2 – interlobular connective tissue; 3 – lumen of the lobe with secretion

**Note:** Hematoxylin and eosin. x 200

**Source:** photo by the authors

The histological structure of the Harderian gland of the experimental chickens 15 days of age was almost the same as that of the control group. A histological examination of the gland of 15-day-old chickens established that the septa divide the gland into secretory

lobes. A large number of blood vessels are noted in the interlobular connective tissue (Fig. 3). The epithelium of the secretory lobules has a pronounced structure and is evenly coloured, and the ducts contain a small amount of secretion.



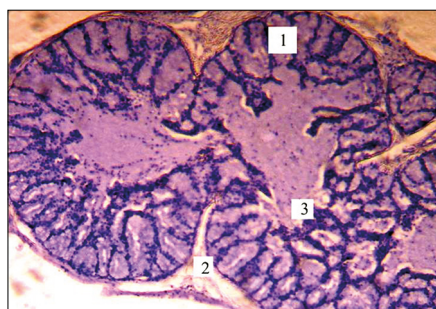
**Figure 3.** The microscopic structure of the Harderian gland of a 15-day-old chicken of the control group:  
1 – secretory lobe; 2 – blood vessels; 3 – interlobular connective tissue

**Note:** Hematoxylin and eosin. x 200

**Source:** photo by the authors

In the group of experimental chickens of 25 days of age (after five times of vaccination), plasma cells appeared in the gland and the appearance of lymphoid clusters was

noted, which were represented by diffuse lymphoid tissue (Fig. 4), and clusters of lymphoid cells were noted in the secretory lobules and the interlobular connective tissue.



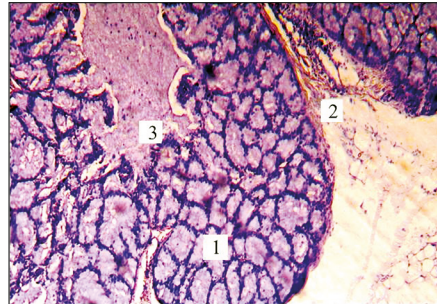
**Figure 4.** The microscopic structure of the Harderian gland of a 25-day-old chicken of the experimental group:  
1 – secretory lobe; 2 – interlobular connective tissue; 3 – diffuse lymphoid tissue

**Note:** Hematoxylin and eosin. x 200

**Source:** photo by the authors

Usually, lymphoid cells are located on the apical part of the glandular lobules. According to these studies, it is during this age period that the ducts of the secretory lobules contain a significant amount of secretion (Fig. 5). Therewith, it was noted that the acini

of the secretory lobules are lined with high columnar epithelium, and their lumens are elongated and somewhat irregular in shape. In this case, the height of the epithelium was  $2.49 \pm 0.11 \mu\text{m}$  and the width was  $1.06 \pm 0.03 \mu\text{m}$ .



**Figure 5.** The microscopic structure of the Harderian gland of the 25-day-old chicken of the experimental group: 1 – secretory lobe; 2 – interlobular connective tissue; 3 – lumen of the lobe

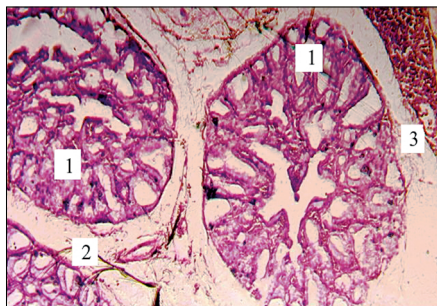
**Note:** Hematoxylin and eosin. x 200

**Source:** photo by the authors

In response to antigenic stimulation, nodular forms of lymphoid tissue appeared in the Harderian gland of the experimental group at 50 days of age (after six vaccinations) (Fig. 6). It was during this period that a significant increase in the thickness of lymphoid structures in vaccinated chickens was observed:

1.11 times ( $P < 0.05$ ) compared to unvaccinated chickens. Therewith, in unvaccinated chickens, this figure was  $20.5 \pm 4.1$  microns, and in vaccinated chickens –  $22.7 \pm 7.4$  microns.

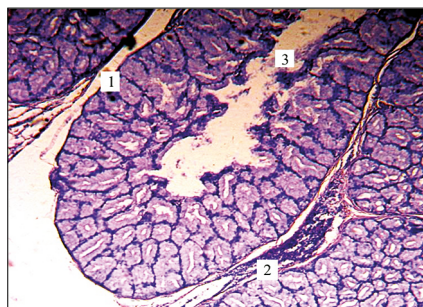
At this age, the ducts of the secretory lobules contain a small amount of secretion (Fig. 7).



**Figure 6.** The microscopic structure of the Harderian gland of a 50-day-old chicken of the experimental group: 1 – secretory lobe; 2 – interlobular connective tissue; 3 – nodular forms of lymphoid tissue

**Note:** Hematoxylin and eosin. x 100

**Source:** photo by the authors



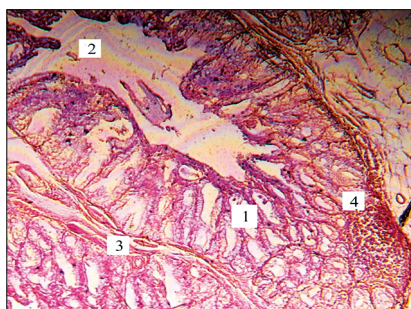
**Figure 7.** The microscopic structure of the Harderian gland of a 50-day-old chicken of the control group: 1 – secretory lobe; 2 – interlobular connective tissue with diffuse lymphoid tissue; 3 – lumen of the lobe

**Note:** Hematoxylin and eosin. x 200

**Source:** photo by the authors

With the age of the bird, the content of the secretion in the lumen of the lobe decreases, and at 100 and 120 days of age, a small amount of it was determined, or not at all. In the chickens of the experimental group

of 75 days of age (after nine times vaccination), penetration of lymphoid tissue into the secretory lobules of the organ was noted (Fig. 8). It is during this age period that 90% of all planned vaccinations of pullets are performed.



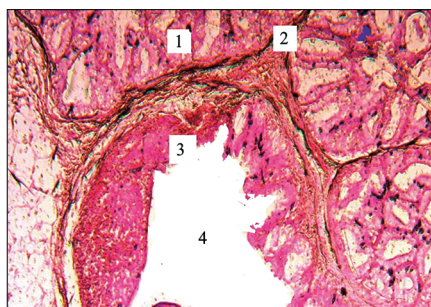**Figure 8.** The microscopic structure of the Harderian gland of the 75-day-old chicken of the experimental group: 1 – secretory lobe; 2 – lumen of the lobe 3 – interlobular connective tissue; 4 – lymphoid tissue

**Note:** Hematoxylin and eosin. x 200

**Source:** photo by the authors

Histological examination of the Harderian gland of 100- and 120-day-old chickens demonstrated a significant proliferation of connective tissue and a significant amount of lymphoid tissue (Figs. 9, 10). Thus, in vaccinated chickens of 100 days of age, the number of nodular lymphoid tissue ranged from 2 to 4 pieces in

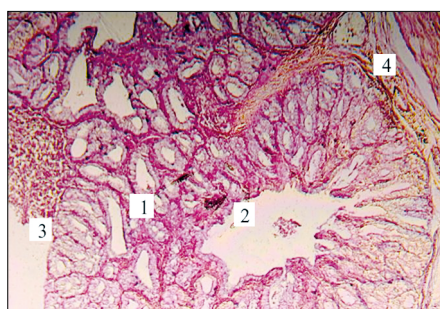
the microscope view (about 10, at 10), and in the control – 1-2 pieces. In addition, when exploring the location of immune formations, their presence was noted in the centre of the lobules, in some cases, the nodular form of lymphoid tissue occupied up to half the area of the secretory lobe of the gland.



**Figure 9.** The microscopic structure of the Harderian gland of a 100-day-old chicken of the experimental group: 1 – secretory lobe; 2 – interlobular connective tissue; 3 – a nodular form of lymphoid tissue; 4 – lumen of the lobe

**Note:** Hematoxylin and eosin. x 200

**Source:** photo by the authors



**Figure 10.** The microscopic structure of the Harderian gland of a 120-day-old chicken of the experimental group: 1 – secretory lobe; 2 – nodular form of lymphoid tissue; 3 – lumen of the lobe; 4 – interlobular connective tissue

**Note:** Hematoxylin and eosin. x 200

**Source:** photo by the authors

In chickens of 75, 100, and 120 days of age, an increase in lymphoid tissue was observed in the postvaccination period both in the interlobular connective tissue and in the secretory lobes of the organ. The results of the study confirm the results of R. Beheiry *et al.* (2020), S. Guralaska *et al.* (2020), who established that the Harderian gland is multilobular, and each lobe consists of secretory acini. In addition, the results of studies by M. Khan *et al.* (2007), according to which this organ of chickens is branched, tubular-alveolar.

In their studies, they noted that the outer capsule of the gland extends inward from the outer capsule of the gland. M. Khan *et al.* (2007) noted that the Harderian gland of the domestic chicken contains thin interlobular connective tissue septa. B. Mobini (2012) observed that the capsule of the organ is constructed of adipose tissue.

The results of the study complement the previous results of S. Guralaska *et al.* (2020), who noted that vaccination of chickens aged 20 days divided the gland parenchyma into secretory lobules. According to the authors, in chickens aged 40 days after vaccination, the appearance of lymphoid tumours, both diffuse and nodular, was noted. According to the results of the study, the diffuse form of lymphoid tissue in chickens in the postvaccination period was already observed at 25 days of age, and the nodular form – was in 50 days old chickens. M. Khan *et al.* (2007) noted in their studies the presence of individual secretory lobules with diffuse lymphoid tissue and nodules. B. Mobini (2012) observed single lymphoid nodules, but they were without germinal centres. P. Bejdic *et al.*, (2014); S. Guralaska & T. Budnik, (2020), S. Guralaska *et al.*, (2020, 2021) in the Harderian gland of chickens up to 40 days of age, no lymph nodes were observed. The gland is rich in densely arranged plasma cells and lymphocytes (Reem & Khattab, 2018; Nagy *et al.*, 2022). According to the results of a morphometric study of the Harderian gland, the number of lymphoid structures is significantly higher in vaccinated chickens. S. Guralaska & T. Budnik, (2020) in their research describe that the size of this gland correlates with the development of lymphoid tissue, since in chickens

in the post-vaccination period, the size of the secretory lobules does not vary significantly from these indicators of intact birds.

According to M.S. Deist & S.J. Lamont (2018), the lymphoid tissue of the gland is understudied, although it is important in local immunity. The Harderian gland has aroused and still arouses interest in the scientific community due to its morphofunctional and phylogenetic characterisation (Santillo *et al.*, 2020; Tybinka *et al.*, 2022). Summarising the results of the studies, it can be noted that the nature of morphological, histological, and morphometric changes in the Harderian gland of chickens in the postvaccination period is most pronounced at 50 and 75 days of age. The analysis of the studies indicates the specifics of the immune response to vaccination inherent in the chicken gland.

## CONCLUSIONS

Postvaccination changes in the histological structure and morphometric parameters in the organ of vaccinated chickens are conditioned upon both the age characteristics of the bird and the frequency of vaccination. Structural changes in the gland of vaccinated chickens indicate the development of humoral and cellular immunity.

It has been established that lymphoid structures of the chicken gland are represented by different levels of organisation of lymphoid tissue, with accumulations of lymphoid structures noted in the interlobular connective tissue and the secretory lobules of the gland. Vaccination stimulates the development of lymphoid tumours, resulting in an increase in their number and size in the glandular gland of chickens, especially at 75, 100 and 120 days of age compared to the control group.

It was established that the ducts of the secretory lobules of the Harderian gland of 25-day-old chickens contain the largest amount of secretion and the smallest amount – at 100 and 120 days of age. In the future, it is planned to conduct a comparative characterisation of the morphological features of the chicken Harderian gland using immunohistochemical and histochemical methods of research.

## REFERENCES

- [1] Beheiry, R.R., Ali, S.A., Aref, M., & Emam, H. (2020). Harderian gland of flying and non-flying birds: Morphological, histological, and histochemical studies. *The Journal of Basic and Applied Zoology*, 81, article number 35. doi: 10.1186/s41936-020-00175-x.
- [2] Bejdic, P., Avdic, R., Amidzic, L., Cutahija, V., Tandir F., & Hadziomerovic, N. (2014). Developmental changes of lymphoid tissue in the harderian gland of laying hens. *Macedonian Veterinary Review*, 37(1), 83-88. doi: 10.14432/j.macvetrev.2014.02.009.
- [3] Deist, M.S., & Lamont, S.J. (2018). What makes the harderian gland transcriptome different from other chicken immune tissues? A gene expression comparative analysis. *Frontiers in Physiology*, 9, article number 492. doi: 10.3389/fphys.2018.00492.
- [4] Dey, S., Pathak D.C., Ramamurthy, N., Maity, H.K., & Chellappa, M.M. (2019). Infectious bursal disease virus in chickens: Prevalence, impact, and management strategies. *Veterinary Medicine: Research and Reports*, 10, 85-97. doi: 10.2147/VMRR.S185159.
- [5] European Convention for the Protection of Vertebrate Animals Used for Experimental and Other Scientific Purposes. (1986, March). Retrieved from <https://rm.coe.int/168007a67b>.

- [6] Feng, Y., Yang, X.J., Wang, Y.B., Li, W.L., Liu, Y., Yin, R.Q., & Yao, J.H. (2012). Effects of immune stress on performance parameters, intestinal enzyme activity and mRNA expression of intestinal transporters in broiler chickens. *Asian-Australasian Journal of Animal Sciences*, 25, 701-707. doi: 10.5713/ajas.2011.11377.
- [7] Frahmmand, S., & Mohammadpour, A.A. (2015). Harderian gland in Canadian ostrich (*Struthio camelus*): A morphological and histochemical study. *Anatomy, Histology, Embryology*, 44(3), 178-185. doi: 10.1111/ah.12123.
- [8] Gimeno, I.M., & Schat, K.A. (2018). Virus-induced immunosuppression in chickens. *Avian Diseases*, 62(3), 272-285. doi: 10.1637/11841-041318-Review.1.
- [9] Guralaska, S., & Budnik, T. (2020). The morphology of the harderian gland chicken's for vaccination and application of AvesstimTM. *Scientific Horizons*, 1(86), 79-88. doi: 10.33249/2663-2144-2020-86-1-79-88.
- [10] Guralaska, S., Kot, T., Dyshliuk, N., Zaika, S., & Khomenko, Z. (2021). Immune response of the harderian gland in chickens to infectious bronchitis coronavirus. *Agricultural Science and Practice*, 8(1), 58-66. doi: 10.15407/agrisp8.01.058.
- [11] Guralaska, S., Kot, T., Pinskyi, O., Sokalyuk, V., & Budnik, T. (2020). Morphofunctional condition of the harderian gland of chickens during the post-vaccine immunity to infectious bronchitis. *Agricultural Science and Practice*, 7(1), 32-39. doi: 10.15407/agrisp7.01.032.
- [12] Jahan, M.R., Islam, M.N., Khan, M.Z.I., Yanai, A., & Shinoda, K. (2018). Morphometry and expression of immunoglobulins-containing plasma cells in the Harderian gland of Birds. *Journal of Advanced Biotechnology and Experimental Therapeutics*, 1(2), 55-60. doi: 10.5455/jabet.2018.d10.
- [13] Kaab, H., Bain, M.M., & Eckersall, P.D. (2018). Acute phase proteins and stress markers in the immediate response to a combined vaccination against Newcastle disease and infectious bronchitis viruses in specific pathogen free (SPF) layer chicks. *Poultry Science*, 97, 463-469. doi: 10.3382/ps/pex340.
- [14] Khan, M.Z.I., Jahan, M.R., Islam, M.N., Haque, Z., Islam, M.R., & Kon, Y. (2007). Immunoglobulin (Ig)- containing plasma cells in the Harderian gland in broiler and native chickens of Bangladesh. *Tissue Cell*, 39, 141-149. doi: 10.1016/j.tice.2007.02.005.
- [15] Kleckowska-Nawrot, J., Gozdziwska-Harlaiczuk, K., Kowalczyk, A., Lukaszewicz, E., & Nowaczyk, R. (2016). Structural differences of the harderian gland between common pheasants (*Phasianus Colchicus Talischensis*) and hybrids of Italian amber and common pheasants. *Brazilian Journal of Science*, 18(2), 309-318. doi: 10.1590/1806-9061-2015-0059.
- [16] Law of Ukraine No. 3447-IV "On the Protection of Animals from Cruelty". (2006, February). Retrieved from <https://zakon.rada.gov.ua/laws/show/3447-15#Text>.
- [17] Madej, J.P., Wozniakowski, G., & Gawel, A. (2016). Morphology of immune organs after very virulent plus strain of Marek's disease virus infection in vaccinated hens. *Polish Journal of Veterinary Sciences*, 19(2), 325-335. doi: 10.1515/pjvs-2016-0040.
- [18] Mobini, B. (2012). Histological and histochemical studies on the Harderian gland in native chickens. *Veterinarni Medicina*, 57, 404-409. doi: 10.17221/6308-VETMED.
- [19] Nagy, N., Olah, I., & Vervelde L. (2022). Structure of the avian lymphoid system. *Avian Immunology*, 3, 11-44. doi: 10.1016/B978-0-12-818708-1.00027-0.
- [20] Nair, V. (2022). Tumors of the avian immune system. *Avian Immunology*, 3, 457-468. doi: 10.1016/B978-0-12-818708-1.00015-4.
- [21] Rana, J., Banubakode, S.B., Patel, S.K., Patil, D.V., & Agrawal, A. (2020). Gross morphological and morphometrical developmental studies on Harderian gland in chicken. *Journal of Animal Research*, 10(2), 325-328. doi: 10.30954/2277-940X.02.2020.23.
- [22] Reem, R.T., & Khattab, M.A. (2018). Macro anatomical and histochemical studies on the orbital glands (lacrimal and harderian glands) in strich (*Struthio camelus*). *International Journal of Advanced Research in Biological Sciences*, 5(1), 1-11. doi: 10.22192/ijarbs.2018.05.01.XXX.
- [23] Reznikov, O.G. (2003). General moral principles of animal experimentation. First National Congress on Bioethics. *Endocrinology*, 8(1), 142-145.
- [24] Saelao, P., Wang, Y., Gallardo, R.A., Lamont, S.J., Dekkers, J.M., Kelly, T., & Zhou, H. (2018). Novel insights into the host immune response of chicken Harderian gland tissue during Newcastle disease virus infection and heat treatment. *BMC Veterinary Research*, 14, article number 280. doi: 10.1186/s12917-018-1583-0.
- [25] Santillo, A., Chieffi Baccari, G., Minucci, S., Falvo, S., Venditti, M., & Di Matteo, L. (2020). The Harderian gland: Endocrine function and hormonal control. *General and Comparative Endocrinology*, 297, article number 113548. doi: 10.1016/j.ygcen.2020.113548.
- [26] Schat, K.A., & Skinner, M.A. (2022). Avian immunosuppressive diseases and immune evasion. *Avian Immunology*, 3, 387-417. doi: 10.1016/B978-0-12-818708-1.00018-X.
- [27] Song, B., Tang, D., Yan, S., Fan, H., Li, G., Shahid, M.S., Mahmood, T., & Guo, Y. (2021). Effects of age on immune function in broiler chickens. *Journal of Animal Science and Biotechnology*, 12, article number 42. doi: 10.1186/s40104-021-00559-1.

- [28] Tybinka, A., Zakrevska, M., & Shchebentovska, O. (2022). Morphometric and histochemical features of the harderian gland in rabbits with different types of autonomous regulation. *Macedonian Veterinary Review*, 45(2), 157-168. doi: 10.2478/macvetrev-2022-0024.
- [29] Universal Declaration on Animal Welfare. (2007, March). Retrieved from [https://web.archive.org/web/20090219033045/http://animalsmatter.org/downloads/UDAW\\_Text\\_2005.pdf](https://web.archive.org/web/20090219033045/http://animalsmatter.org/downloads/UDAW_Text_2005.pdf).
- [30] Wilkinson, K.G., Tee, E., Tomkins, R.B., Hepworth, G., & Premier, R. (2011). Effect of heating and aging of poultry litter on the persistence of enteric bacteria. *Poultry Science*, 90, 10-18. doi: 10.3382/ps.2010-01023.
- [31] Wit, J.J., Dijkman, R., Guerrero, P., Calvo, J., Gonzalez, A., & Hidalgo, H. (2017). Variability in biological behaviour, pathogenicity, protectotype and induction of virus neutralizing antibodies by different vaccination programmes to infectious bronchitis virus genotype Q1 strains from Chile. *Avian Pathology*, 46(6), 666-675. doi: 10.1080/03079457.2017.1346782.
- [32] Yang, X., Zhou, Y., Li, J., Fu, L., Ji, G., Zeng, F., Zhou, L., Gao, W., & Wang, H. (2016). Recombinant infectious bronchitis virus (IBV) H120 vaccine strain expressing the hemagglutinin-neuraminidase (HN) protein of Newcastle disease virus (NDV) protects chickens against IBV and NDV challenge. *Archives of Virology*, 161(5), 1209-1216. doi: 10.1007/s00705-016-2764-4.
- [33] Yang, X.J., Li, W.L., Feng, Y., & Yao, J.H. (2011). Effects of immune stress on growth performance, immunity, and cecal microflora in chickens. *Poultry Science*, 90, 2740-2746. doi: 10.3382/ps.2011-01591.

## Гістоархітектоніка гардерової залози курей в поствакцинальний період

Тетяна Сергіївна Буднік, Світлана Василівна Гуральська, Олег Вікентійович Пінський,  
Геннадій Петрович Грищук, Володимир Васильович Гончаренко

Поліський національний університет  
10008, б-р Старий, 7, м. Житомир, Україна

**Анотація.** Розуміння впливу вакцинації на організм курей неможливе без вивчення морфології органів імунного захисту. Метою дослідження було виявлення морфологічних змін гардерової залози курей кросу хайсекс браун віком 1, 15, 25, 50, 75, 100 та 120-добового віку за впливу вакцинації. В дослідження було використано наступні методи: анатомічні, гістологічні, світлооптичні, морфометричні, статистичні. Було проаналізовано гістопрепарати гардерової залози курей різного віку (1, 15, 25, 50, 75, 100 та 120 діб) вакцинованої та невакцинованої групи. Було досліджено на гістологічних препаратах гардерової залози курей особливості будови органу, його лімфоїдних утворень та їх типи форм. Згідно гістологічних досліджень було встановлено, що це складна трубчасто-часточкова залоза, яка складається із секреторних часточок із протоками. Міжчасточкова сполучна тканина містить значну кількість лімфоцитів, плазмоцитів та інших клітин. У вакцинованих курей 25-добового віку відмічали наявність дифузної лімфоїдної тканини, якої не відмічали у контрольній групі, а у 50-добовому віці – утворення вузликуватої форми лімфоїдної тканини, максимальна кількість яких спостерігається у 100-добовому віці. У курей 75, 100 та 120-добового віку дослідної групи в гардеровій залозі зростала кількість лімфоїдної тканини, наявність якої відмічали в міжчасточковій сполучній тканині та секреторних часточках. Було доведено, що гардерова залоза курей, як периферичний орган імунного захисту, формується в 50-добовому віці як контрольної, так і вакцинованої групи. Вивчення морфологічних змін у гардеровій залозі птиці різного віку є важливим інструментом формування протоколів профілактичних щеплень у сучасному птахівництві. Отримані результати дослідження необхідно враховувати при удосконаленні технології вирощування, експлуатації курей, щоб забезпечити високу життєдіяльність і відповідно продуктивність

**Ключові слова:** птиця, гістологічні зміни, лімфоїдні утворення, секреторні часточки, вакцинація